

# Lingual thyroid: diagnosis using a hybrid of single photon emission computed tomography and standard computed tomography

J DOLEZAL<sup>1</sup>, J VIZDA<sup>1</sup>, J HORACEK<sup>2</sup>, S SPITALNIKOVA<sup>3</sup>

<sup>1</sup>Department of Nuclear Medicine and <sup>2</sup>Second Department of Internal Medicine, Charles University in Prague, Faculty of Medicine in Hradec Kralove and Charles University Teaching Hospital, Hradec, Kralove, Czech Republic and <sup>3</sup>Department of Nuclear Medicine, Hospital Havlickuv Brod, Czech Republic

## Abstract

**Aim:** To present a rare case of lingual thyroid detected using a hybrid of single photon emission computed tomography and standard computed tomography in a young woman with hypothyroidism.

**Materials and methods:** A 29-year-old woman was screened for autoimmune thyroid disorders in early pregnancy, and found to have subclinical hypothyroidism. No thyroid tissue was found in the anterior neck upon ultrasonography, raising suspicions of an ectopic thyroid. The patient was treated with levothyroxine throughout the remainder of her pregnancy, and developed postpartum thyroiditis requiring an increase in levothyroxine dosage. Whole-body scintigraphy and zoomed static head and neck scintigraphy were performed. Abnormal <sup>99m</sup>Tc-pertechnetate uptake was observed in the oral region, whereas no uptake was found in the usual thyroid location. Hybrid imaging using single photon emission computed tomography and standard computed tomography was performed to improve three-dimensional representation of the area of increased activity.

**Results:** The latter imaging modality detected ectopic thyroid tissue in the tongue.

**Conclusion:** Whole body <sup>99m</sup>Tc-pertechnetate scintigraphy and a hybrid of single photon emission computed tomography and standard computed tomography are effective imaging modalities for the investigation of ectopic thyroid tissue. The latter modality is particularly recommended, as it allows more precise spatial visualisation of increased isotope uptake activity in the head and neck.

**Key words:** Thyroid Gland; Thyroid Dysgenesis; Lingual Thyroid; Diagnosis; Tomography, Emission-Computed, Single Photon

## Introduction

Ectopic thyroid is an uncommon embryological abnormality characterised by the presence of thyroid tissue in a site other than its usual pre-tracheal location.<sup>1</sup> Ectopic thyroid tissue results from developmental defects at early stages of thyroid gland embryogenesis, during its passage from the floor of the primitive foregut to its final pre-tracheal position.<sup>2</sup> Lingual thyroids have an incidence of 1:3000 to 1:10 000.<sup>3</sup>

Thyroid scintigraphy utilising <sup>99m</sup>Tc-pertechnetate disodium or <sup>123</sup>I plays a vital role in diagnosing this disorder.<sup>2</sup> Head and neck imaging using single photon emission computed tomography and the newly introduced hybrid of single photon emission computed tomography plus standard computed tomography (CT) enables three-dimensional (3D) image acquisition and display, while at the same time improving imaging interpretation and thyroid scintigraphy accuracy in patients with suspected ectopic thyroid tissue.

Here, we present a rare case of a lingual thyroid detected using a hybrid of single photon emission computed tomography and standard CT in a young woman with hypothyroidism.

## Case report

Following screening for autoimmune thyroid disorders during pregnancy,<sup>4</sup> a 29-year-old woman in the 13th gestational week was referred to our endocrine clinic due to an increased level of thyroid-stimulating hormone (TSH; also known as thyrotropin).

Further investigations confirmed an elevated TSH concentration (7.35 mU/l; reference range, 0.15–5 mU/l) together with a low to normal level of free thyroxine (T<sub>4</sub>; 11.58 pmol/l; reference range, 11–25 pmol/l) and a normal free tri-iodothyronine level (T<sub>3</sub>; 3.15 pmol/l; reference range, 2.5–5.8 pmol/l). The level of antibodies against thyroid peroxidase was not elevated.

Ultrasonography of the anterior neck revealed the absence of thyroid tissue in the usual location.

There were no clinical symptoms or signs of hypothyroidism. Levothyroxine was administered (50 µg per day, later increased to 75 µg per day) to treat the patient's subclinical hypothyroidism during her pregnancy.

After a full-term pregnancy, she gave birth to a healthy son. Three months later, the patient's thyroid status was normal (TSH, 3.97 mU/l; free T<sub>4</sub>, 15.68 pmol/l; free T<sub>3</sub>,

4.08 pmol/l), following ongoing thyroxine replacement therapy. Although her thyroid peroxidase antibody level was retested and was again found to be normal, post-partum thyroiditis was suspected due to elevation of the serum thyroglobulin concentration (to more than twice the normal range). Indeed, the patient's thyroxine dose had to be further increased, to 125 µg per day, during follow up.

When the patient stopped breast-feeding (approximately 12 months after delivery), we performed  $^{99m}\text{Tc}$ -pertechnetate disodium scintigraphy to locate her endogenous source of thyroid hormones. Whole-body scintigraphy and zoomed static head and neck scintigraphy were performed 15 minutes after administering  $^{99m}\text{Tc}$ -pertechnetate disodium (200 MBq) intravenously. An area of pathological  $^{99m}\text{Tc}$ -pertechnetate uptake was observed in the oral region, with no uptake in the normal anatomical location of the thyroid gland.

To improve 3D visualisation of the area of increased activity, we also used a hybrid of single photon emission computed tomography plus standard CT. A rotating, dual-head, hybrid single photon emission computed tomography and standard CT scanner (Infinia Hawkey 4; GE, Fairfield, Connecticut, USA) with infrared body contouring and a large field of view was used. The images were evaluated using Xeleris processing systems (GE). Using this system, we detected  $^{99m}\text{Tc}$ -pertechnetate uptake in the tongue, indicating ectopic thyroid tissue (Figure 1).

### Discussion

Our finding of a lingual ectopic thyroid in a young woman, identified using  $^{99m}\text{Tc}$ -pertechnetate disodium thyroid scintigraphy and a hybrid of single photon emission computed tomography and standard CT, is similar to other, previously

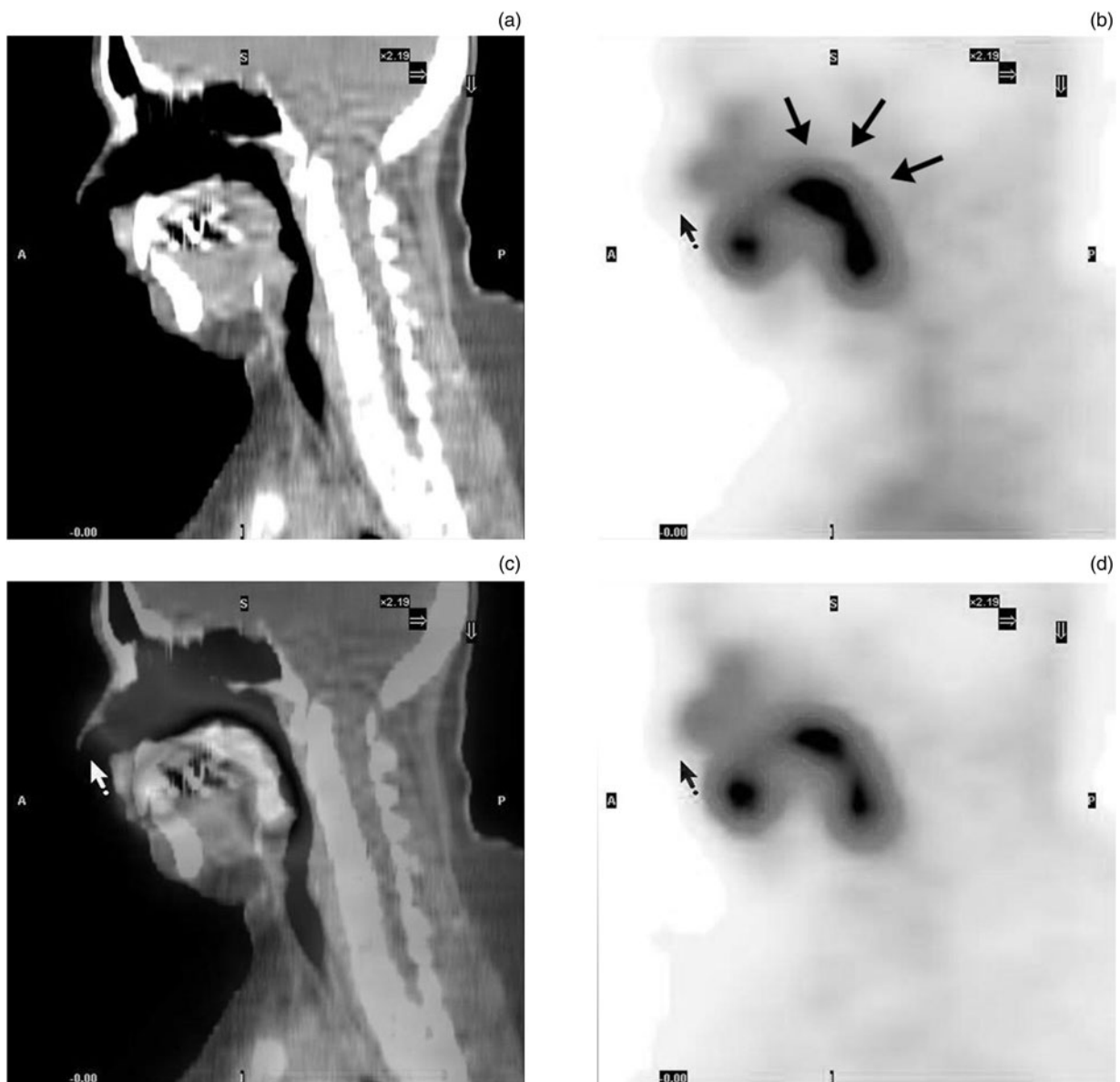


FIG. 1

Head and neck imaging (sagittal views) using a hybrid of single photon emission computed tomography and standard computed tomography (CT): (a) standard CT, (b) single photon emission computed tomography with attenuation correction, (c) fusion single photon emission computed tomography plus standard CT, and (d) single photon emission computed tomography without attenuation correction. Uptake of  $^{99m}\text{Tc}$ -pertechnetate disodium in the ectopic lingual thyroid tissue is seen (plain arrows). A = anterior; P = posterior

reported cases. Deshmukh *et al.*<sup>5</sup> reported a 44-year-old patient with ectopic thyroid tissue in the submandibular space. Ulug *et al.*<sup>6</sup> described a case of dual ectopic thyroids in the lingual and infrahyoid areas in a 20-year-old woman who had no thyroid gland in its normal anatomical location. Eli *et al.*<sup>7</sup> reported a case of ectopic thyroid tissue presenting as a submandibular mass in a patient with hyperthyroidism. Zackaria *et al.*<sup>3</sup> presented a case of multinodular lingual goitre in a 66-year-old woman with dysphagia, in whom a previously silent lingual thyroid had undergone multinodular change, causing the reported symptoms; the goitre was excised. Gorur *et al.*<sup>8</sup> reported a patient with an ectopic mediastinal goitre and Graves' disease. Pelizzo *et al.*<sup>9</sup> used ultrasound and <sup>99m</sup>Tc-pertechnetate disodium scintigraphy to detect the coexistence of submandibular ectopic thyroid tissue in the lateral neck with a normally located and functional thyroid gland, in a 54-year-old man with a 6-month history of a visible, asymptomatic swelling in the right submandibular region.

- Ectopic thyroid tissue is effectively detected by whole body <sup>99m</sup>Tc-pertechnetate scintigraphy
- A hybrid of single photon emission computed tomography plus standard computed tomography enables better three-dimensional imaging of head and neck ectopic thyroids

### Conclusion

Whole body <sup>99m</sup>Tc-pertechnetate scintigraphy is an effective imaging modality for ectopic thyroid tissue in patients who have no thyroid gland in the normal anatomical location. In order to improve 3D visualisation of the ectopic thyroid, head and neck imaging using a hybrid of single photon emission computed tomography and standard CT is recommended.

### Acknowledgements

This work was supported by the Czech Ministry of Health (research project code MZO 00179906).

### References

- 1 Yang YS, Hong KH. Case of thyroid hemiagenesis and ectopic lingual thyroid presenting as goitre. *J Laryngol Otol* 2008;**122**:e17
- 2 Noussios G, Anagnostis P, Goulis DG, Lappas D, Natsis K. Ectopic thyroid tissue: anatomical, clinical and surgical implications of a rare entity. *Eur J Endocrinol* 2011;**165**:375–82
- 3 Zackaria M, Chisholm EJ, Tolley NS, Rice A, Chhatwani A. Multinodular goitre in lingual thyroid: case report. *J Laryngol Otol* 2010;**124**:349–51
- 4 Horacek J, Spitalnikova S, Dlabalova B, Malirova E, Vizda J, Svilias I *et al.* Universal screening detects two-times more thyroid disorders in early pregnancy than targeted high-risk case finding. *Eur J Endocrinol* 2010;**163**:645–50
- 5 Deshmukh AD, Katna R, Patil A, Chaukar DA, Basu S, D'Cruz AK. Ectopic thyroid masquerading as submandibular tumour: a case report. *Ann R Coll Surg Engl* 2011;**93**:77–80
- 6 Ulug T, Ulubil SA, Alagol F. Dual ectopic thyroid: report of a case. *J Laryngol Otol* 2003;**117**:574–6
- 7 Eli SU, Marnane C, Peter R, Winter S. Ectopic, submandibular thyroid causing hyperthyroidism. *J Laryngol Otol* 2011;**125**:1091–3
- 8 Gorur GD, Isgoren S, Tan YZ, Utkan Z, Demir H, Berk F. Graves' disease in a patient with ectopic mediastinal thyroid. *Clin Nucl Med* 2011;**36**:1039–40
- 9 Pelizzo MR, Torresan F, Grassetto G, Briani G, Cristina Marzola M, Rubello D. Imaging identifies submandibular ectopic thyroid tissue. *Clin Nucl Med* 2011;**36**:728–30

Address for correspondence:

Associate Professor Jiri Dolezal,  
Department of Nuclear Medicine,  
Charles University Teaching Hospital,  
Sokolska 581,  
Hradec Kralove,  
Czech Republic, 500 05

Fax: +420 495834512  
E-mail: [dolezal@fnhk.cz](mailto:dolezal@fnhk.cz)

---

Associate Professor J Dolezal takes responsibility for the integrity of the content of the paper  
Competing interests: None declared

---